

# Intra Operative Ziehl-Neelsen Test to Establish Diagnosis of Osteoarticular Tuberculosis Case: A Case Report and Literature Review from Multifocal Osteoarticular Tuberculosis Case

Aryadi Kurniawan<sup>1</sup> and Samuel Maruanaya<sup>2</sup>

<sup>1</sup>Consultant of Pediatric Division, Staff of Department of Orthopaedic and Traumatology, Faculty of Medicine, University of Indonesia, Dr Cipto Mangunkusumo Hospital, Jakarta Indonesia

<sup>2</sup>Department of Orthopaedic and Traumatology, Faculty of Medicine, University of Indonesia, Cipto Mangunkusumo Hospital, Jakarta Indonesia

**Received:** September 23, 2019

**Accepted:** October 22, 2019

**Published:** November 3, 2019

**Abstract: Background:** Multifocal osteoarticular tuberculosis, one of the various forms of extra-pulmonary tuberculosis, is uncommon. The symptoms are nonspecific, and the disease often presents with an indolent clinical course, usually leading to a delayed diagnosis as well as bone and joint destruction. Till now, golden standard of diagnosis is made by confirming Mycobacterium organism from biopsy.

**Methods:** We deliver a case of sixteen-year-old boy patient with pain on bilateral ankle and left elbow since 1 month before admission, there was no history of previous trauma or known infection. Radiologic examination has been conduct but unconcluded. He was given antibiotic and NSAIDS but still yet to improve clinically. He then went to surgically open biopsy and run examination using wet prep dye from bone biopsy sample with Ziehl–Neelsen stain, compare by Acid Fast Bacillus (AFB) culture, PCR and histopathologic test.

**Result:** Acid fast bacillus was found on wet prep dye with Ziehl-Neelsen stain in sample from left distal tibia. Diagnosis was made multifocal osteoarticular tuberculosis, which confirmed using AFB culture, PCR and histopathologic examination. We have done debridement and the patient receive anti tuberculosis therapy for nine months.

**Discussion:** In this case report we want emphasize the use of wet prep dye with Ziehl-Neelsen stain intra operative to reduce waiting time result from histopathologic and microbiologic test which normally need several days to confirm the result.

**Keywords:** Multifocal Osteoarticular Tuberculosis, wet prep dye with Ziehl–Neelsen stain, Bone Biopsy.

## Introduction

Tuberculosis remains a major international problem despite advances in radiological diagnosis and anti-tuberculous therapy. It affects approximately one-third of the world's population; each year there are about 20 million prevalent cases and 8 million new cases.<sup>1</sup> Osteoarticular/ skeletal tuberculosis as a form of extra pulmonary TB forms 1-4.3% of all TB cases and 5-15% of all EPTB.<sup>2</sup>

The metaphysis of the long bones of the lower limbs and the small bones of the hand and feet are most commonly affected.<sup>3</sup> Multifocal skeletal tuberculosis, one of the various forms of extra-pulmonary tuberculosis, is uncommon.

The symptoms are nonspecific, and the disease often presents with an indolent clinical course, usually leading to a delayed diagnosis as well as bone and joint destruction.<sup>4</sup> Early diagnosis and

initiation of appropriate treatment is desirable to minimize extent of local disease and potential increased functional disability.<sup>5</sup>

Accurate diagnosis in osteoarticular tuberculosis poses a difficulty due to deep inaccessible lesions, paucibacillary state, and initiation of empirical ATT in most of the cases.<sup>6</sup> Because of the overlap in imaging appearances between tuberculosis and other diseases, even in cases considered typical of tuberculosis, one still should aim to confirm the presence of *Mycobacterium tuberculosis* either by biopsy or aspiration before commencement of anti-tuberculous therapy.<sup>3,7</sup>

Confirming biopsy result as soon as possible is important to start anti-tuberculous therapy. Intra operative Ziehl-Neelsen stain from wet prep bone biopsy sample can establishing the diagnosis and initiate early treatment of anti-tuberculosis therapy.

In this report, we present a case of multifocal osteoarticular tuberculosis of right distal tibia and talus, left calcaneus, and left distal humerus confirmed by AFB stain, AFB culture, PCR, and histopathology. Patient was treated surgically by debridement continued by anti-tuberculosis therapy.

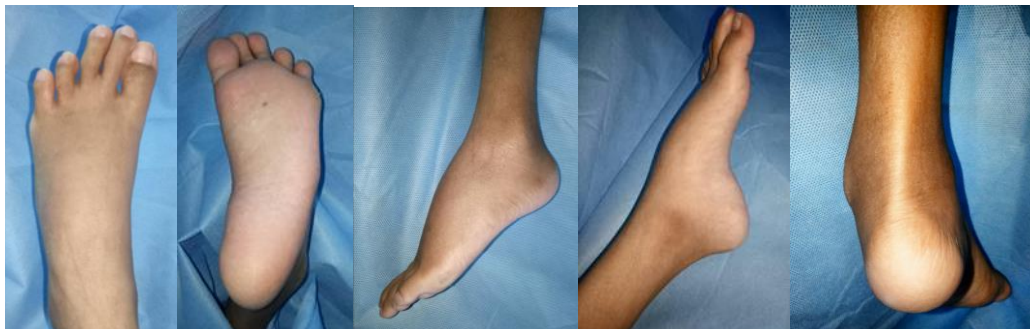### **Case Illustration**

A 16-year-old boy admitted to our center with a pain on bilateral ankles and left elbow since 1 month before admissions. Pain on bilateral ankle and left elbow since 1 month before admission, pain is exaggerated by movement. Pain on right ankle is also accompanied with an ulcerated wart.

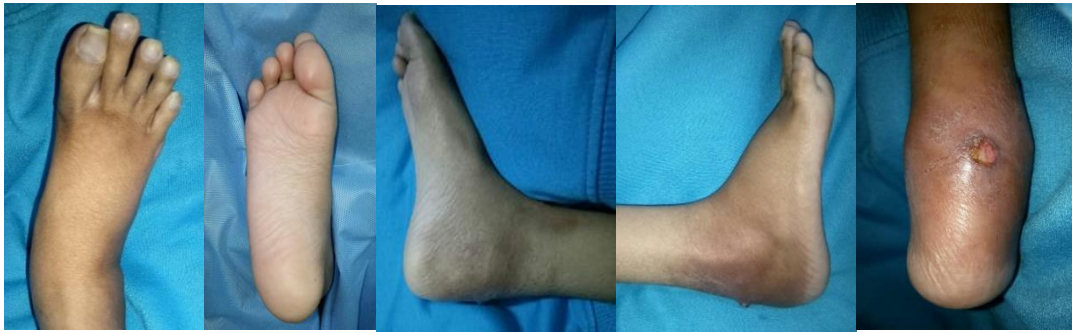Patient had fever mostly at night. There was no history of previous trauma or known infection. At the age of two, patient have history of abscess on his left ankle and left elbow that has been operated. In hospital admission, the patient was administered antibiotic, NSAID, but still yet to improve clinically. The patient had congenital heart defect (moderately sized atrial septal defect) and marasmus-type severe malnutrition.

On local examination of left ankle there was equines deformity of right foot, patient feel tenderness with capillary refill time below 2 seconds, and normal distal sensory. Range of movement is limited due to contracture of the ankle. On local examination of right ankle there was ulcerated wart on posterior aspect of the ankle, patient feel tenderness with capillary refill time below 2 seconds, and normal distal sensory.

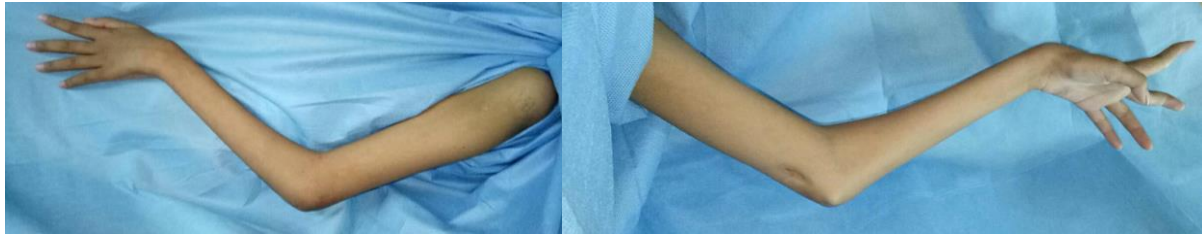Range of movement is limited due to pain. On local examination of left elbow there was surgical scar on posterior aspect of the elbow, tender on palpation with normal distal sensorium. Range of movement is 20° on flexion but 120° on extension due to contracture.



**Figure 1. Physical examination of left ankle**



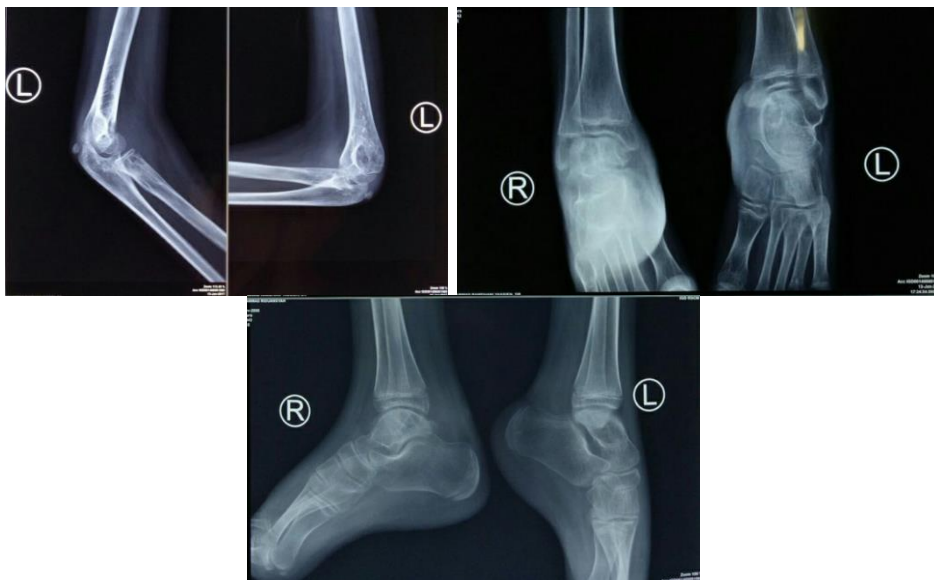
**Figure 2. Physical examination of right ankle**



**Figure 3. Physical examination of left elbow**

Laboratory test was showing leukocytosis (12.030 /uL) with neutrophil count was 88,3% and ESR 101 mm. C reactive protein was 98,5 mg/L, Procalcitonin 3,22 ng/ml, Rheumatoid factor was normal (less than 11,4 IU/mL), ANA test is positives. Liver blood test shows elevated liver enzymes (AST 67 U/L, ALT 59 U/L). Blood culture test is sterile, swab culture from ulcerated wart is showing no microorganism growth.

On presentation to our center, a radiograph for left elbow, and bilateral ankle was taken and shown multiple lytic lesion and soft tissue swelling suspected to be an osteomyelitis lesion.



**Figure 4. Radiograph of left elbow and bilateral ankle**

MRI is taken for left elbow and bilateral ankle. Hipo-intens lesion on distal metaphysis right tibia, right talus and right navicular, right talo-tibial joint is narrowed with fluid collection. Lesion on right talus is destructive, creating tract connected to cutis on posterior-lateral region of the right ankle. Hipo-intens lesion on distal right tibia and fibula, right talus, right calcaneus-navicular-cuboid-cuneiform-base third metatarsal, especially after contrast injection. On left elbow, MRI show thickening of synovium elbow without fluid accumulation.

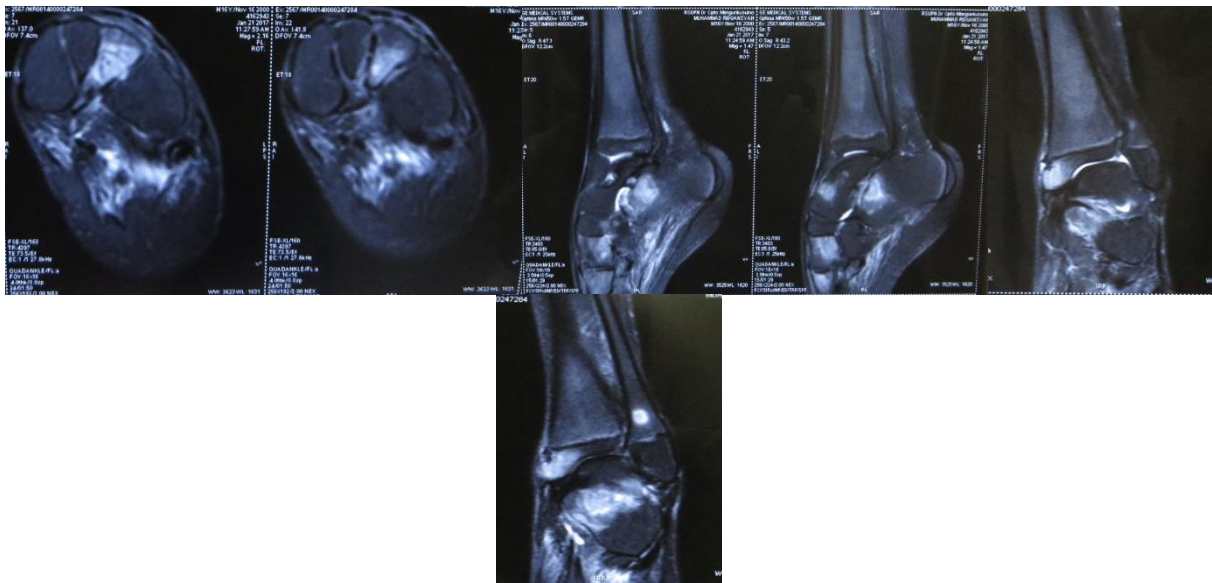


Figure 5. MRI of right ankle

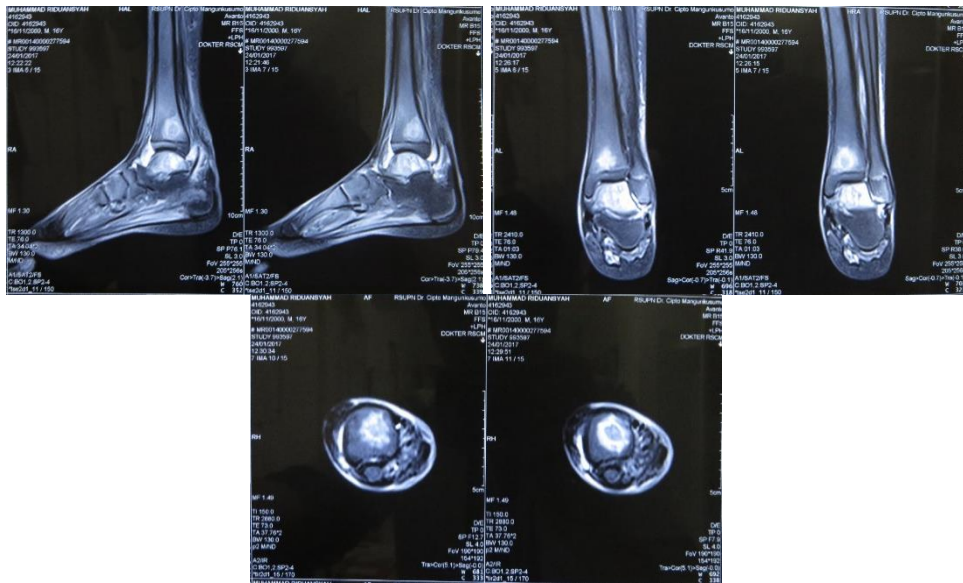


Figure 6. MRI of left ankle

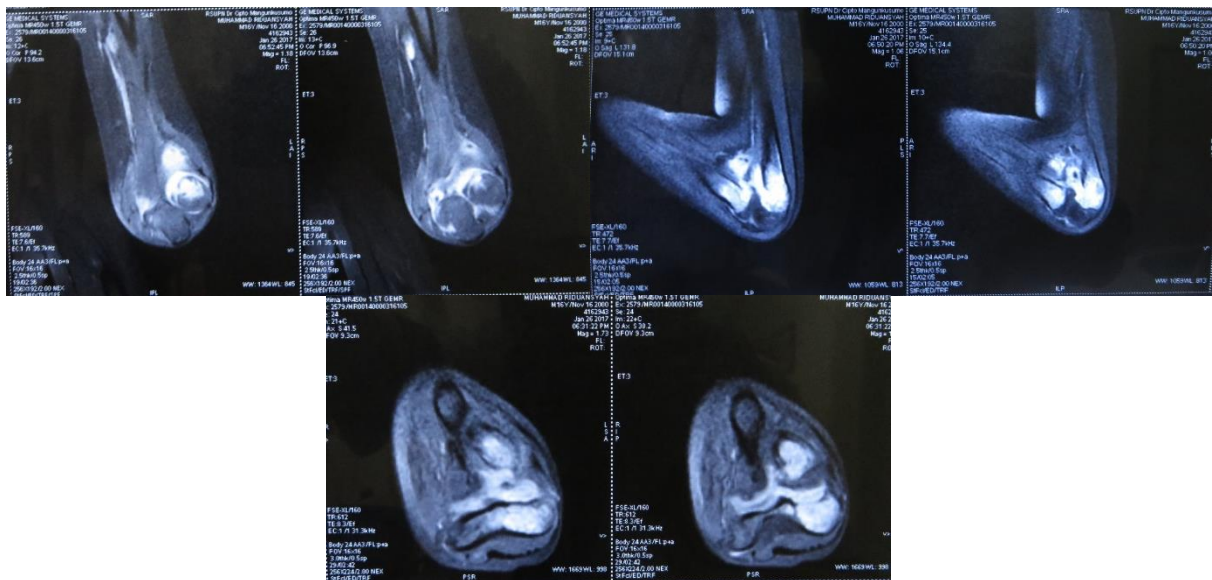
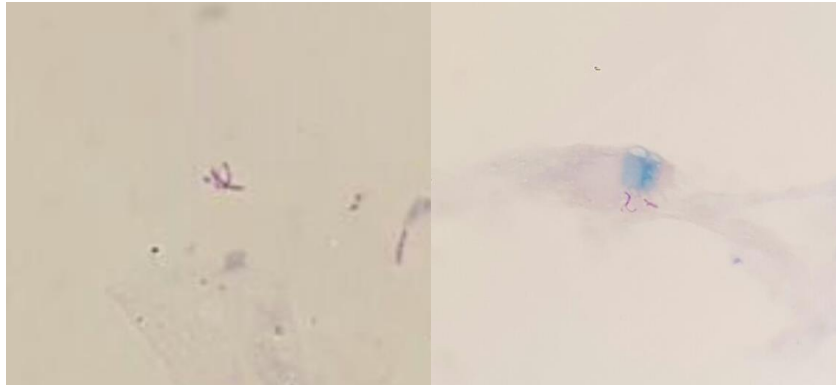


Figure 7. MRI of left elbow

We conduct a surgical intervention with biopsy continued by debridement for left elbow and bilateral ankle. Decision to continue the operation with debridement is based on examination from fresh sample wet prep dye with Ziehl–Neelsen stain which come positive for acid fast bacilli. Biopsy sample is also sent for AFB culture, histopathologic, PCR test to compare the result. Post operatively, patient received anti tuberculosis therapy for duration of nine months.



**Figure 8. Acid fast bacilli (Ziehl-Neelsen smear) from biopsy sample intra-operative**

Histopathologic result shows fibrotic tissue surround by acute and chronic inflammation cell, necrotic tissue bone with positive acid fast bacilli for more likely osteomyelitis appearance from *Mycobacterium atypic*. Microbiology test with real time polymerase chain reaction is positive for *Mycobacterium tuberculosis* from synovium and bone marrow. AFB culture was come positive for mycobacterium colony growth.

### **Discussion**

Multifocal skeletal tuberculosis is defined as osteoarticular lesions that occur simultaneously at two or more locations.<sup>8</sup> Bone lesions are usually solitary because sensitization of the patient has already occurred before the onset of skeletal disease. If the host immunity is poor, the immune response may be altered leading to multiple lesions.<sup>9</sup> Multifocal osteoarticular tuberculosis in children is not uncommon in under-developed countries where tuberculosis is endemic. Its description in English literature is both brief and sparse. Multiple osteolytic lesions in a child usually suggest disseminated malignancy. Disseminated bone tuberculosis, because of its rarity, is often neglected as a diagnostic possibility.<sup>9</sup> The spine and weight-bearing joints are most commonly affected but the mycobacterium can infect any bone, joint, tendon, or bursa.<sup>10</sup> Delayed diagnosis of tuberculous infection in the extra-axial bones and joints may allow progression to joint deformity.<sup>7,11</sup>

Accurate diagnosis in osteoarticular tuberculosis poses a difficulty due to deep inaccessible lesions, paucibacillary state, and initiation of empirical ATT in most of the cases. Subjecting all cases to panel of investigations including AFB staining, AFB culture/sensitivity, PCR, and histopathology on obtaining tissue have been proved more efficacious than resorting to single test. Tissue diagnosis still remains the gold standard.<sup>6</sup>

The main presentation of multifocal osteoarticular tuberculosis in children is swelling, pain, discharging sinus, deformity, and loss of range of movement.<sup>8,12</sup> Our patient has symptom of pain, loss of range of movement and deformity. Mild pain and swelling of bone, with slight warmth and tenderness, and overlying swelling of soft tissue should alert clinicians to the possibility of skeletal tuberculosis.

### **Laboratory finding**

Our patient Mantoux test was come negative, may be due to mal-nutrient marasmus type. Leukocyte and Erythrocyte sedimentation rate is elevated showing infection. C-reactive protein and procalcitonin was high show inflammation

A complete blood count (CBC) is useful for evaluating leukocytosis and anemia. The leukocyte count rarely exceeds 15,000/ $\mu$ L acutely and is usually normal in chronic osteomyelitis.<sup>13</sup> The erythrocyte sedimentation rate (ESR) and C reactive protein (CRP) are often elevated; however, they both lack specificity in the absence of other radiologic and microbiologic data.<sup>14</sup> In cases of proven osteomyelitis, both tests may be used to assess response to therapy or relapse. CRP may be more reliable than ESR for assessing response to treatment in children.<sup>14</sup>

Blood cultures are positive in about 50% of the paediatric cases, while bone aspirates may give positive results in 70% of the cases.<sup>15,16</sup> Culture remains the gold standard for the diagnosis of tuberculosis and brucellosis. Lakhanpal et al. reported 49.53% positivity by AFB (Acid-Fast Bacillus) culture sensitivity.<sup>17</sup> However, as both *Brucella* spp and *Mycobacterium tuberculosis* are slowly growing pathogens, cultures are labor intensive, which can at times lead to unacceptable delays in diagnosis. Furthermore, cultures can be very insensitive in some cases of extra-pulmonary tuberculosis and focal forms of brucellosis.<sup>18</sup> To overcome certain limitations of conventional microbiological techniques, PCR-based assays may be useful for the diagnosis of both tuberculosis and human brucellosis.<sup>18</sup> The use of real-time PCR technology reduces the time to identification of bacterial DNA directly from clinical samples. Additionally, considerable time and effort can be saved by simultaneously amplifying multiple sequences in a single reaction. This strategy, named Multiplex PCR, has proven to be very useful in different clinical scenarios.<sup>18-20</sup>

### **Imaging studies**

Plain radiography and MRI in our patient show unclear view of osteomyelitis. Plain radiograph only shows multiple lytic lesion which differentiated diagnosis to infection and neoplasm. MRI view show osteomyelitis appearance.

Plain radiography has low sensitivity and specificity for detecting acute osteomyelitis.<sup>21</sup> As many as 80% of patients who present in the first two weeks of infection onset will have a normal radiograph.<sup>22</sup> Plain radiographs will demonstrate soft-tissue swelling with loss of joint surface definition.<sup>6</sup> With disease progression, marginal erosions may be seen. Cartilage loss and joint space destruction are late findings. Periarticular bone loss may be striking.<sup>7</sup> Phemister's triad (juxta-articular osteoporosis, peripheral osseous erosions, and gradual joint space narrowing) suggests tuberculous arthritis but is nonspecific.<sup>3</sup> Despite its limitations, plain radiography should still be the first-line imaging test in suspected osteomyelitis, as it is useful for excluding other differentials such as fractures.<sup>21</sup> The specificity of plain radiographs for the detection of osteomyelitis is higher than its sensitivity, and because of this, use of alternative imaging methods such as scintigraphic modalities and MRI has been prompted.<sup>23</sup>

Magnetic resonance imaging (MRI) can be extremely helpful in unclear situations. This imaging modality is particularly useful when a patient is suspected of having osteomyelitis, discitis or septic arthritis involving the axial skeleton and pelvis.<sup>24</sup> MRI is a highly sensitive technique which demonstrates fine anatomical details and identifies the early changes of arthritis, which are not visible on radiographs.<sup>25</sup> MRI also provides greater spatial resolution in delineating the anatomic extension of infection.<sup>26</sup> MRI findings in osteomyelitis usually are related to the replacement of marrow fat with water secondary to edema, exudate, hyperemia, and bone ischemia. Findings include the following: decreased signal intensity in the involved bone on T1-weighted images, increased signal intensity in the involved bone on T2-weighted image, and increased signal intensity in the involved bone on short-tau inversion recovery (STIR) images.<sup>27</sup> MRI allows early detection of osteomyelitis and assessment of the extent of involvement and the activity of the disease in cases of chronic bone infection.<sup>23</sup> MRI advantages go far beyond diagnosis only, helping the surgeon to plan the optimal surgical management. The sensitivity of MRI has been reported to be as high as 98%, compared with 53% for bone scintigraphy, with additional benefit of MRI in visualizing subperiosteal abscess, pyomyositis, septic arthritis, and deep venous thrombosis.<sup>28</sup> MRI features consistent with tuberculous arthritis include bone marrow edema, cortical erosions, synovitis, joint

effusions, tenosynovitis, soft tissue collection, and myositis.<sup>27</sup> Disadvantages of MRI are its occasional inability to distinguish infectious from reactive inflammation and its difficulty imaging sites with metallic implants, such as joint prostheses or fixation devices.<sup>23</sup>

### **Ziehl–Neelsen stain**

In this case report we want to emphasize the use of wet prep dye with Ziehl-Neelsen stain intra operative to reduce waiting time result from histopathologic and microbiologic test which normally need several days to confirm the result. Intra operatively, there was sample taken from the soft tissue around the joint, half the sample is taken to histopathologic and microbiology lab, half other is examine directly staining with Ziehl-Neelsen. Acid fast bacilli were found positive. This result confirmed several days ahead when the histopathological come positive with appearances of osteomyelitis more likely from *Mycobacterium atypical*. Microbiology real time PCR examination shows DNA positive *Mycobacterium tuberculosis*.

Tuberculosis are gram positive, and using acid-fast histochemical stains, such as Ziehl-Neelsen stain, they appear as red rod-shaped structures that are 2-4  $\mu\text{m}$  in length and 0,2-0,5  $\mu\text{m}$  in diameter. Acid-fast organisms like *Mycobacterium* contain large amounts of lipid substances within their cell walls called mycolic acids. These acids resist staining by ordinary methods such as a Gram stain. The Ziehl–Neelsen stain, also known as the acid-fast stain, was first described by two German doctors: the bacteriologist Franz Ziehl (1859–1926) and the pathologist Friedrich Neelsen (1854–1898). It is a special bacteriological stain used to identify acid-fast organisms, mainly *Mycobacteria*.

A typical AFB stain procedure involves dropping the cells in suspension onto a slide, then air drying the liquid and heat fixing the cells. The slide is flooded with Carbol-Fuchsin, which is then heated to dry and rinsed off in tap water. The slide is then flooded with a 1% solution of hydrochloric acid in isopropyl alcohol (or methanol) to remove the carbol fuchsin, thus removing the stain from cells that are unprotected by a waxy lipid layer. Thereafter, the cells are stained in methylene blue and viewed on a microscope under oil immersion.

Hallmark of staining is Ziehl–Neelsen (ZN) technique which is the easiest and quickest diagnostic test with a limited sensitivity (46–78%) but specificity is virtually 100%. ZN staining requires 105 bacilli/mL. Osteoarticular disease is a paucibacillary disease and hence ZN stain positivity.<sup>6</sup>

A large number of organisms required by all the above methods were the major limitation in detection of *M. tuberculosis*. A single test, which would amplify the genome, even if a single organism was present, was thought to be ideal for detection of paucibacillary TB cases. The PCR can analyze the expression of genes even from single cells.<sup>6</sup> PCR is not a substitute for culture; it is an addition to the routine battery of laboratory tests for the rapid and definitive diagnosis of TB.

Treatment of extra-pulmonary tuberculosis incorporates the same principles as treatment of pulmonary tuberculosis. However, treatment durations are extended up to nine months for bone and joint tuberculosis.<sup>29</sup> Our patient undergo anti tuberculosis drugs with regimen Rifampicin 375 mg, Isoniazid 250 mg, Pyrazinamide 750 mg, and Ethambutol 500 mg, the treatment is planning for 9-month period.

### **Conclusion**

In conclusion, we presented a case of 16-year-old male with Multifocal tuberculous osteomyelitis of Right distal tibia and talus, left calcaneus, and left distal humerus. Diagnostic was made by confirming wet prep dye from biopsy using Ziehl-Neelsen staining. The patient is treated surgically by debridement directly administrate of anti-tuberculosis therapy. AFB culture, PCR, and histopathologies examination confirmed the diagnosis of Osteoarticular tuberculosis one-week post-operative.

## **References**

1. Raviglione, M.C., Dixie E Snider, J.R. and Kochi, A. 1996. Global epidemiology of tuberculosis: morbidity and mortality of a worldwide epidemic. *Survey of Anesthesiology*, 40(2): 127.
2. Arathi, N., Ahmad, F. and Huda, N. 2013. Osteoarticular tuberculosis-a three years' retrospective study. *Journal of Clinical and Diagnostic Research: JCDR*, 7(10): 2189.
3. Griffith, J.F., Kumta, S.M., Leung, P.C., Cheng, J.C., Chow, L.T. and Metreweli, C. 2002. Imaging of musculoskeletal tuberculosis: a new look at an old disease. *Clinical Orthopaedics and Related Research*, 398: 32-39.
4. de Araujo, P.S.R., de Melo, H.R.L., de Melo, F.L., Medeiros, Z., Maciel, M.A., Florêncio, R. and Brandão, E. 2015. Multifocal skeletal tuberculosis in an immunocompetent patient: a case report. *BMC Infectious Diseases*, 15(1): 235.
5. Magnussen, A., Dinneen, A. and Ramesh, P. 2013. Osteoarticular tuberculosis: increasing incidence of a difficult clinical diagnosis. *British Journal of General Practice*, 63(612): 385-386.
6. Vardhan, V. and Yanamandra, U. 2011. Diagnosis of osteoarticular tuberculosis. *Indian Journal of Rheumatology*, 6(1): 87-94.
7. Moore, S.L. and Rafii, M. 2001. Imaging of musculoskeletal and spinal tuberculosis. *Radiologic Clinics of North America*, 39(2): 329-342.
8. Yilmaz, M.H., Kantarci, F., Mihmanli, I. and Kanberoglu, K. 2004. Multifocal skeletal tuberculosis. *Southern Medical Journal*, 97(8): 785-788.
9. Kumar Dhammi, I., Kumar Jain, A., Singh, S., Aggarwal, A. and Kumar, S. 2003. Multifocal skeletal tuberculosis in children: a retrospective study of 18 cases. *Scandinavian Journal of Infectious Diseases*, 35(11-12): 797-799.
10. Zychowicz, M.E. 2010. Osteoarticular manifestations of Mycobacterium tuberculosis infection. *Orthopaedic Nursing*, 29(6): 400-406.
11. Vohra, R., Kang, H.S., Dogra, S., Saggarr, R.R. and Sharma, R. 1997. Tuberculous osteomyelitis. *The Journal of Bone and Joint Surgery. British Volume*, 79(4): 562-566.
12. Agarwal, A., Khan, S.A. and Qureshi, N.A. 2011. Multifocal osteoarticular tuberculosis in children. *Journal of Orthopaedic Surgery*, 19(3): 336-340.
13. Gross, T., Kaim, A.H., Regazzoni, P. and Widmer, A.F. 2002. Current concepts in posttraumatic osteomyelitis: a diagnostic challenge with new imaging options. *Journal of Trauma and Acute Care Surgery*, 52(6): 1210-1219.
14. Fritz, J. M. and McDonald, J.R. 2008. Osteomyelitis: approach to diagnosis and treatment. *The Physician and Sports Medicine*, 36(1): 50-54.
15. Chiappini, E., Mastrangelo, G. and Lazzeri, S. 2016. A case of acute osteomyelitis: an update on diagnosis and treatment. *International Journal of Environmental Research and Public Health*, 13(6): 539.
16. Russell, C.D., Ramaesh, R., Kalima, P., Murray, A. and Gaston, M.S. 2015. Microbiological characteristics of acute osteoarticular infections in children. *Journal of Medical Microbiology*, 64(4): 446-453.
17. Lakhanpal, V. P., Tuli, S.M., Singh, H. and Sen, P.C. 1974. The value of histology, culture and guinea pig inoculation examination in osteo-articular tuberculosis. *Acta Orthopaedica Scandinavica*, 45(1-4): 36-42.



18. Queipo-Ortuño, M.I., Colmenero, J.D., Bermudez, P., Bravo, M.J. and Morata, P. 2009. Rapid differential diagnosis between extrapulmonary tuberculosis and focal complications of brucellosis using a multiplex real-time PCR assay. *PLoS One*, 4(2): e4526.
19. Strålin, K., Törnqvist, E., Kaltoft, M.S., Olcén, P. and Holmberg, H. 2006. Etiologic diagnosis of adult bacterial pneumonia by culture and PCR applied to respiratory tract samples. *Journal of Clinical Microbiology*, 44(2): 643-645.
20. Markoulatos, P., Georgopoulou, A., Kotsovassilis, C., Karabogia- Karaphillides, P. and Spyrou, N. 2000. Detection and typing of HSV- 1, HSV- 2, and VZV by a multiplex polymerase chain reaction. *Journal of Clinical Laboratory Analysis*, 14(5): 214-219.
21. Lee, Y.J., Sadigh, S., Mankad, K., Kapse, N. and Rajeswaran, G. 2016. The imaging of osteomyelitis. *Quantitative Imaging in Medicine and Surgery*, 6(2): 184.
22. Jaramillo, D. 2011. Infection: musculoskeletal. *Pediatric Radiology*, 41(1): 127-134.
23. Pineda, C., Espinosa, R. and Pena, A. 2009. Radiographic imaging in osteomyelitis: the role of plain radiography, computed tomography, ultrasonography, magnetic resonance imaging, and scintigraphy. In *Seminars in Plastic Surgery*, 23(02): 080-089.
24. Abernethy, L.J. and Carty, H. 1997. Modern approach to the diagnosis of osteomyelitis in children. *British Journal of Hospital Medicine*, 58(9): 464-468.
25. Sawlani, V., Chandra, T., Mishra, R.N., Aggarwal, A., Jain, U.K. and Gujral, R.B. 2003. MRI features of tuberculosis of peripheral joints. *Clinical Radiology*, 58(10): 755-762.
26. Meyers, S.P. and Wiener, S.N. 1991. Diagnosis of hematogenous pyogenic vertebral osteomyelitis by magnetic resonance imaging. *Archives of Internal Medicine*, 151(4): 683-687.
27. Parmar, H., Shah, J., Patkar, D., Singrakhia, M., Patankar, T. and Hutchinson, C. 2004. Tuberculous arthritis of the appendicular skeleton: MR imaging appearances. *European Journal of Radiology*, 52(3): 300-309.
28. Browne, L.P., Mason, E.O., Kaplan, S.L., Cassady, C.I., Krishnamurthy, R. and Guillerman, R. P. 2008. Optimal imaging strategy for community-acquired *Staphylococcus aureus* musculoskeletal infections in children. *Pediatric Radiology*, 38(8): 841-847.
29. Inge, L.D. and Wilson, J.W. 2008. Update on the treatment of tuberculosis. *American Family Physician*, 78(4): 9.

**Citation:** Aryadi Kurniawan and Samuel Maruanaya. 2019. Intra Operative Ziehl-Neelsen Test to Establish Diagnosis of Osteoarticular Tuberculosis Case: A Case Report and Literature Review from Multifocal Osteoarticular Tuberculosis Case. *International Journal of Recent Innovations in Medicine and Clinical Research*, 1(2): 7-15.

**Copyright:** This is an open-access article distributed under the terms of the Creative Commons Attribution License, which permits unrestricted use, distribution, and reproduction in any medium, provided the original author and source are credited. **Copyright©2019;** Aryadi Kurniawan and Samuel Maruanaya (2019).